

· 临床研究 ·

超声心动图不同切面测量正常胎儿大动脉内径的对比

周婷, 吴云, 杨玲, 叶夏慧

南京医科大学附属妇产医院 南京市妇幼保健院超声科, 江苏 南京 210004

摘要: **目的** 分析中晚期胎儿在左、右室流出道切面和三血管切面测量主动脉与肺动脉内径获得参数之间的关系与差异,探讨大动脉定量评估的最佳测量方法。**方法** 选取2019年9月至2020年9月南京医科大学附属妇产医院常规行胎儿超声心动图检查的孕周24~30周的980名孕妇,行胎儿生长指标测量。分别于左、右室流出道切面测量胎儿主动脉内径(AO)、肺动脉内径(PA),三血管切面测量主动脉内径(AO'),肺动脉内径(PA')。在标准四腔心切面于心室舒张末期分别测量左心室横径(LVW)、左心室纵径(LVL)、右心室横径(RVW)、右心室纵径(RVL)。比较不同切面测量获得的主动脉内径(AO与AO')、主肺动脉内径(PA与PA')、大动脉内径比值(AO/PA与AO'/PA')。分析上述各变量间的规律性,各变量与心室径线间的相关性。对两种不同切面测量大动脉内径所获得参数进行对比分析。**结果** (1)流出道切面和三血管切面测得的AO、PA、AO'、PA'均与孕周呈线性正相关($r=0.858, 0.821, 0.803, 0.070, P<0.01$),AO/PA、AO'/PA'与孕周无相关性($P>0.05$)。(2)流出道切面、三血管切面测得的AO[(4.44±0.27)mm vs (4.54±0.36)mm, $P<0.01$]、PA[(5.24±0.30)mm vs (5.34±0.45)mm, $P<0.01$]差异有统计学意义,AO/PA差异无统计学意义(0.84±0.35 vs 0.85±0.12, $P>0.05$)。(3)AO与LVW及LVL呈正相关($r=0.330, 0.247, P<0.01$),AO'与LVW与LVL呈正相关($r=0.191, 0.156, P<0.01$),AO与LVW及LVL的相关性更高。PA与RVW及RVL呈正相关($r=0.262, 0.181, P<0.01$),PA'与RVW及RVL呈正相关($r=0.114, 0.164, P<0.01$),PA与RVW及RVL的相关性更高。**结论** 流出道切面可作为测量大动脉内径的常规切面,三血管切面可作为测量大动脉内径的辅助切面。两种测量方法联合运用可准确评估心室及大动脉的发育情况。

关键词: 超声心动图; 胎儿; 主动脉内径; 肺动脉内径; 流出道切面; 三血管切面

中图分类号: R714.5 R540.45 **文献标识码:** B **文章编号:** 1674-8182(2022)03-0360-04

Comparison of different views of echocardiography in measuring the great artery diameters of normal fetuses

ZHOU Ting, WU Yun, YANG Ling, YE Xia-hui

Department of Ultrasound, Women's Hospital of Nanjing Medical University

(Nanjing Maternity and Child Health Care Hospital), Nanjing, Jiangsu 210004, China

Corresponding author: WU Yun, E-mail: 405877652@qq.com

Abstract: Objective To analyze the relationship and differences of the inner diameters of aorta and pulmonary artery measured by left and right ventricular outflow view and the three-vessels view echocardiography in normal fetuses during the second and late trimesters to explore the best measurement method for quantitative evaluation of the great arteries.

Methods From September 2019 to September 2020, 980 pregnant women who received routine fetal echocardiography at 24-30 gestational weeks in Women's Hospital of Nanjing Medical University were selected for fetal growth index measurement. Fetal aortic (AO) diameter and pulmonary artery (PA) diameter were measured by left and right ventricular outflow tract view(AO,PA) and three-vessel view(AO',PA'), respectively. Left ventricular width (LVW), left ventricular-length(LVL), right ventricular width (RVW) and right ventricular-length(RVL) were measured at the end of ventricular diastole by the standard four-chamber view. The values of AO and AO', PA and PA', AO/PA and AO'/PA' measured in different view were compared. The regularity of the above variables and the correlation between the

DOI: 10.13429/j.cnki.cjcr.2022.03.014

基金项目: 南京市卫生科技发展专项资金项目 (YKK18155)

通信作者: 吴云, E-mail: 405877652@qq.com

variables and ventricular diameter were analyzed. The parameters obtained by measuring the diameter of large artery in two different view were compared and analyzed. **Results** The values of AO, PA, AO' and PA' measured in outflow tract view and three vessel view were linearly and positively correlated with gestational weeks ($r=0.858, 0.821, 0.803, 0.070, P<0.01$), while AO/PA and AO'/PA' were not correlated with gestational weeks ($P>0.05$). There were significant differences in AO [(4.44±0.27) mm vs (4.54±0.36) mm] and PA [(5.24±0.30) mm vs (5.34±0.45) mm] measured in outflow tract view and three vessel view ($P<0.01$), but there was no significant difference in AO/PA (0.84±0.35 vs 0.85±0.12, $P>0.05$). AO and AO' were positively correlated with LVW ($r=0.330, 0.247, P<0.01$) and LVL ($r=0.191, 0.156, P<0.01$). PA and PA' were positively correlated with RVW ($r=0.262, 0.181, P<0.01$) and RVL ($r=0.114, 0.164, P<0.01$). AO and PA had higher correlation with LVW, LVL, RVW and RVL. **Conclusion** Ventricular outflow tract view in echocardiography can be used as a routine view in measuring the inner diameter of cardiac arteries of fetuses, with the three-vessels view as an auxiliary method. Combined application of the different view helps to evaluate the normal development of ventricle and great artery in fetuses.

Keywords: Echocardiography; Fetus; Aortic diameter; Pulmonary artery diameter; Ventricular outflow tract view; Three-vessels view

Fund program: Nanjing Municipal Health Science and Technology Development Special Fund Project (YKK18155)

胎儿先天性心脏病(先心病)是最常见的出生缺陷,先心病除了心房、心室结构异常,还表现为大动脉的连接及形态异常。主动脉、肺动脉内径值或两者比例异常往往是胎儿严重先心病最常见的一种表现^[1]。胎儿超声心动图检查时通过测量与心室连接的两根大动脉内径评估胎儿的心脏发育情况,因此,胎儿主动脉及肺动脉的测量精准性尤为重要。目前临床上还没有统一的公认标准来测量两根大动脉内径。本研究分别从流出道切面和三血管切面测量主动脉及肺动脉内径,研究两根大动脉的生长规律,比较两种测量方法获得各变量间的关系,同时分析大动脉内径值与其相连接的心室径线的相关性,以探讨对大动脉定量评估的最佳测量方法。

1 资料与方法

1.1 一般资料 本研究为回顾性研究。选取2019年9月至2020年9月于南京医科大学附属妇产医院超声科常规行胎儿超声心动图检查的孕妇980例,所有胎儿均为单胎,经中孕期系统筛查,胎儿大小符合孕龄且无结构畸形。孕妇年龄22~43(35.2±6.5)岁,孕周24~30(26.3±2.7)周。排除标准:羊水过多或过少、卵圆孔及动脉导管血流受限、胎儿心律不齐、孕妇过度肥胖导致图像质量不满意。

1.2 仪器与方法 采用Siemens Acuson Sequoia 512彩色超声诊断仪,探头型号6C2,频率2~6 MHz。受检孕妇采取仰卧位,必要时采取侧卧位。常规测量胎儿生长生物学指标:双顶径、头围、腹围及股骨长,对胎儿心脏进行详细扫查。胎儿心脏检查时选取胎儿心脏扫查模式。根据美国胎儿超声心动图学会

(ASE)指南和检查标准进行规范扫查^[2]。依次保存胎儿标准四腔心切面,左心室流出道切面,右心室流出道切面,三血管切面,三血管气管切面,主动脉弓切面,上、下腔静脉切面。测量并记录以下数据:(1)左心室流出道切面测量主动脉内径(AO);(2)右心室流出道切面测量肺动脉内径(PA);(3)三血管切面测量主动脉内径(AO')、肺动脉内径(PA');(4)标准四腔心切面测量左心室横径(LVW)、左心室纵径(LVL)及右心室横径(RVW)、右心室纵径(RVL)。测量注意要点:(1)心脏放大占屏幕2/3,测量数据需反复测量3次取平均值;(2)流出道切面在收缩期主动脉瓣、肺动脉瓣完全开放时,于瓣环水平测量AO、PA(图1A、图1B);(3)三血管切面测量时在主肺动脉长轴的垂直方向由左前向右后依次测量AO'、PA'(图1C);(4)于标准心尖四腔心切面心室舒张末期测量心室内径,以心室内膜面作为测量起止点(图1D)。

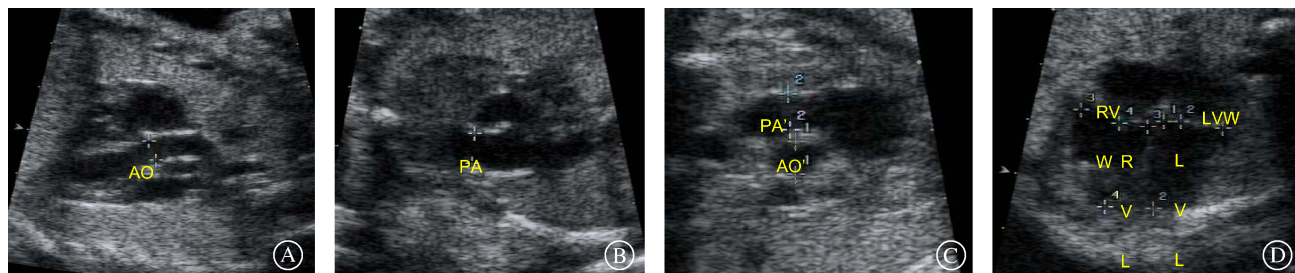
1.3 统计学方法 采用SPSS 22.0软件进行数据分析。计量资料以 $\bar{x}\pm s$ 表示,绘制散点图。两种方法测得各变量数据间的对比分析采用配对 t 检验。采用Pearson相关分析不同切面测得的大动脉内径和同侧心室各径线以及与孕周的相关性。 $P<0.05$ 为差异有统计学意义。

2 结果

2.1 AO、PA、AO'、PA'与孕周相关性分析 AO、PA、AO'、PA'均与孕周呈正相关($r=0.858, 0.821, 0.803, 0.070, P<0.01$),且 $AO<PA, AO'<PA'$ 。不同切面测得的内径比值AO/PA、AO'/PA'与孕周无相关性。

2.2 不同切面的大动脉内径参数比较 流出道切面、三血管切面测得的 AO、PA 差异有统计学意义

($P < 0.01$), AO/PA 差异无统计学意义 ($P > 0.05$)。见表 1。



注: A 为左室流出道切面,收缩末期主动脉瓣环水平测量 AO; B 为右室流出道切面,收缩末期肺动脉瓣环水平测量 PA; C 为三血管切面由左前向右后依次为主肺动脉、主动脉、上腔静脉,测量 AO'、PA'; D 为标准四腔心切面,舒张末期测量 LVW、RVW、LVL、RVL,在同一切面测量。

图 1 胎儿心脏检查超声心动图测量要点示意图

Fig. 1 Schematic diagram of the main points of echocardiography measurement of fetal heart examination

表 1 不同切面的大动脉内径参数比较 ($n = 980, \bar{x} \pm s$)

Tab. 1 Comparison of internal diameter parameters of great arteries in different sections ($n = 980, \bar{x} \pm s$)

类别	AO(mm)	PA(mm)	AO/PA
流出道切面	4.44±0.27	5.24±0.30	0.84±0.35
三血管切面	4.54±0.36	5.34±0.45	0.85±0.12
t 值	6.957	5.788	0.846
P 值	<0.001	<0.001	0.398

2.3 同切面大动脉内径与同侧心室参数相关系数 AO 与 LVW 及 LVL 呈正相关 ($r = 0.330, 0.247, P < 0.01$), AO' 与 LVW 及 LVL 呈正相关 ($r = 0.191, 0.156, P < 0.01$), AO 与 LVW 及 LVL 的相关性更高。PA 与 RVW 及 RVL 呈正相关 ($r = 0.262, 0.181, P < 0.01$), PA' 与 RVW 及 RVL 呈正相关 ($r = 0.114, 0.164, P < 0.01$), PA 与 RVW 及 RVL 的相关性更高。

3 讨论

胎儿大动脉发育异常包括大动脉连接异常和形态异常。其中大动脉的形态异常多表现为主动脉及主肺动脉内径的异常或者主、肺动脉的比例异常。胎儿心腔的大小能较早地评估胎儿心脏发育情况,心脏大动脉内径大小与胎儿心室大小密切相关^[3]。一侧心室流出道或与之连接的大动脉细窄会导致同侧心房及心室因血流量减少而缩小,而对侧的心房、心室及大动脉会因血流量的增多而增大^[4]。由于胎儿期卵圆孔与动脉导管的持续存在,胎儿期左心系统与右心系统不同于新生儿期的“并联关系”而呈“串联关系”,胎儿的心输出量为左、右心室联合心输出量^[5]。当胎儿在宫内仅出现一侧心室的 cardiac 功能改变时,胎儿此时的联合心输出量能维持在正常范围,可以满足胎儿各脏器及胎盘灌注的需求,因此胎儿在宫内仍能继续生存。然而新生儿一旦出生后,由于血流动力学

发生改变,极有可能发生新生儿死亡^[6]。此类严重先天性心脏病在宫内没有其他的异常表现,仅表现为大动脉的内径比例异常或左、右心室腔的不对称^[7-8]。主动脉内径过小即左侧的流出道血流量减少,进入体循环的血流量减少,导致左心系统变小,同时右心系统代偿性增大。此表现可见于左心发育不良综合征、主动脉狭窄、主动脉弓离断等左心系统病变。同理,肺动脉内径缩小使肺循环血流量减少,导致右心系统变小,可见于肺动脉狭窄或闭锁的情况,或者是因三尖瓣病变引发的肺血流量的减少^[9-10]。主动脉内径增大可见于前向型对位不良型室缺、法洛四联症、永存动脉干畸形。肺动脉内径增大常见于肺动脉瓣狭窄后的扩张、肺动脉瓣缺如,亦可发生于血流动力学异常引起的右心增大,如卵圆孔和动脉导管的血流受限、三尖瓣的返流等^[11]。

胎儿超声心动图检查中,单纯诊断心室的减小或发育不良比较困难,心腔大小测量数据较多,受体位影响较大,定量评估受影响因素较多,不能简便快捷地评估心脏发育情况。临床上常采用测量主动脉与肺动脉内径来快速评估心脏发育,因此选取准确的测量切面及方法精确测量出大动脉内径在评估胎儿心脏发育异常尤为重要^[12]。本研究在左、右心室流出道切面和三血管气管切面分别测量大动脉内径,两种测量切面的图像获得率均较高,与文献报道一致^[13]。流出道切面为主动脉及主肺动脉的长轴切面,可显示大动脉与心室的连接关系、主动脉瓣及肺动脉瓣的瓣膜启闭情况,是测量主动脉和肺动脉的常用切面。三血管切面作为筛查圆锥动脉干畸形的重要切面,受胎儿体位影响较小,可以在同一切面同时测量主动脉与主肺动脉内径,简单易操作,临床上也经常于此切面进行快速

测量及评估。该切面除提供大动脉内径及其比值等信息,也是提供主动脉、肺动脉及动脉导管解剖关系的重要切面^[14]。本研究中,不同切面测得大动脉内径间差异有统计学意义。三血管切面较流出道切面更向头侧倾斜,所获得肺动脉主干段位于肺动脉瓣后接近左、右肺动脉分叉部,此处肺动脉壁略膨出,所测得内径数据略大于流出道切面。而此切面显示的主动脉位于升主动脉起始部,接近主动脉窦部,稍微膨大,所测得内径数据亦略偏大。本研究中,两种切面测得的大动脉内径均与同侧心室大小呈正相关,且流出道切面测得的数据相关系数更高,即流出道切面测得的数据与心室大小的改变关系更密切,更能反映心室大小的变化情况。然而不管是在流出道切面,还是在三血管切面测量的大动脉内径均符合肺动脉内径大于主动脉内径。有研究表明,在流出道切面测量获得的主动脉与肺动脉内径之比相对恒定,并不随孕周变化而改变^[15],本研究结果与其相一致。另外,本研究将三血管切面获得的主动脉与肺动脉内径比值亦进行了分析,发现同样比值较恒定,同时与流出道切面所测进行对比,发现两组数值间差异无统计学意义,因此在该切面获得的主、肺动脉内径值同样具有参考价值。

综上所述,流出道切面可作为常规切面测量大动脉内径。三血管切面测量所得数据也具有其规律性,且该切面能帮助识别心脏大动脉排列畸形,可作为测量大动脉内径的辅助切面。上述两切面相互联合,定量分析,可为胎儿心脏结构畸形及部分功能异常提供诊断线索,为产前诊断及预后评估提供依据。

参考文献

- [1] Lee MY, Won HS. Technique of fetal echocardiography [J]. *Obstet Gynecol Sci*, 2013, 56(4): 217-226.
- [2] Rychik J, Ayres N, Cuneo B, et al. American Society of Echocardiography guidelines and standards for performance of the fetal echocardiogram [J]. *J Am Soc Echocardiogr*, 2004, 17(7): 803-810.
- [3] DeVore GR, Satou G, Sklansky M. Area of the fetal heart's four-chamber view: a practical screening tool to improve detection of cardiac abnormalities in a low-risk population [J]. *Prenat Diagn*, 2017, 37(2): 151-155.
- [4] Beattie M, Peyvandi S, Ganesan S, et al. Toward improving the fetal diagnosis of coarctation of the aorta [J]. *Pediatr Cardiol*, 2017, 38(2): 344-352.
- [5] Nakata M, Sakuma J, Takano M, et al. Assessment of fetal cardiac function with echocardiography [J]. *J Obstet Gynaecol Res*, 2020, 46(1): 31-38.
- [6] Toole BJ, Schlosser B, McCracken CE, et al. Importance of relationship between ductus and isthmus in fetal diagnosis of coarctation of aorta [J]. *Echocardiography*, 2016, 33(5): 771-777.
- [7] Wong SF, Ward C, Lee-Tannock A, et al. Pulmonary artery/aorta ratio in simple screening for fetal outflow tract abnormalities during the second trimester [J]. *Ultrasound Obstet Gynecol*, 2007, 30(3): 275-280.
- [8] Gabbay-Benziv R, Demir BC, Crimmins S, et al. Retrospective case series examining the clinical significance of subjective fetal cardiac ventricular disproportion [J]. *Int J Gynaecol Obstet*, 2016, 135(1): 28-32.
- [9] Chen KB, Gu Q, Xia T, et al. Three-vessel-Trachea view in the diagnosis of fetal cardiac great vessel malformation [J]. *J Biol Regul Homeost Agents*, 2018, 32(2): 351-355.
- [10] Idilman IS, Ipek A, Balaban M, et al. Fetal aorta larger than the main pulmonary artery on the three-vessel view: correlation with postnatal echocardiographic findings [J]. *J Clin Ultrasound*, 2016, 44(7): 423-428.
- [11] Guirado L, Crispi F, Masoller N, et al. Biventricular impact of mild to moderate fetal pulmonary valve stenosis [J]. *Ultrasound Obstet Gynecol*, 2018, 51(3): 349-356.
- [12] 李江华,高磊,周伟娜,等.超声检测胎儿心脏生长指标与孕龄关系的临床价值[J].*医学影像学杂志*, 2020, 30(1): 144-147.
Li JH, Gao L, Zhou WN, et al. Study on the relationship between ultrasonic fetal heart growth indexes and gestational age [J]. *J Med Imaging*, 2020, 30(1): 144-147.
- [13] Vettraino IM, Lee W, Bronsteen RA, et al. Sonographic evaluation of the ventricular cardiac outflow tracts [J]. *J Ultrasound Med*, 2005, 24(4): 566.
- [14] 王红鸽,杨军,韩舒,等.三血管及三血管气管切面在超声产前诊断胎儿心脏大血管畸形中的应用价值[J].*中国临床医学影像杂志*, 2015, 26(3): 192-196.
Wang HH, Yang J, Han S, et al. Value of three-vessel view plus three vessels and Trachea view in ultrasonic diagnosis of fetal heart and great vessel malformations [J]. *J China Clin Med Imaging*, 2015, 26(3): 192-196.
- [15] Gu XY, He YH, Zhang Y, et al. Fetal echocardiography: reference values for the Chinese population [J]. *J Perinat Med*, 2017, 45(2): 171-179.

收稿日期:2021-10-30 修回日期:2021-11-12 编辑:王宇